

One Reason Eye Problems are no Joke: Corneal Stromal Abscesses

We've all dreaded it: the eye emergency. There are numerous eye emergencies, and the bottom line is if your horse is squinting, tearing, has discoloration in the eye or the eye is swollen it should be looked at by a veterinarian. Complications and compromise to the eye can occur if left untreated or if treated with the wrong medications. Let's take a look at one of these complications: stromal abscess, which may result in loss of vision or expensive surgery to save the eye. Stromal abscesses are usually sequelae to (a consequence of) minor corneal ulcerations in the horse. The cornea is made up of several layers. The protective outer layer is the epithelium, and the inner layer that separates the cornea from the anterior chamber of the eye is called the endothelium. The layer between these two structures is the stroma.

The pathogenesis:

A stromal abscess forms when the stromal layer is inoculated with a surface or environmental organism such as bacteria or fungus. How does this happen? There is first a break in the epithelial barrier, which can be caused by an ulceration, puncture, laceration or foreign body. Then infection sets in when the organism enters the deeper layers of the cornea. The body tries to heal this defect in the epithelium, and often re-epithelializes (or seals over) the defect, and traps the unwanted organisms inside. Neutrophils are a type of white blood cell that is recruited to the area in an effort of immune defense. However, neutrophils in this area of the eye can be detrimental. They release enzymes (proteins) whose job it is to destroy the inciting organism, but in the wake of this defense they also degrade healthy stromal cells. This inflammatory process causes ocular pain. It is not always the case that there is an infectious component causing the stromal abscess. A horse can have what is called a sterile abscess where no etiologic agent is found, and therefore they are with out a bacterial or fungal cause. It is solely the inflammatory response that causes accumulation of white blood cells in the stromal layer, which leads to the clinical disease. Sterile stromal abscesses are still sequelae to a break in the epithelial layer, and are most common.

The clinical picture:

A stromal abscess will look like a very dense yellow to white opacity (cloudiness) within the cornea. This is an accumulation of white blood cells, as a result of the organisms infecting the cornea (bacteria or fungus). In Figure 1 you can see a typical stromal abscess where the cellular infiltrate is seen as the yellow dense opacity that is settled at the bottom of the cornea. You can also see the small red vessels within the cornea as the body attempts to heal the stromal abscess. The cellular infiltrate (white blood cells) can be well demarcated or have diffuse and hazy edges.

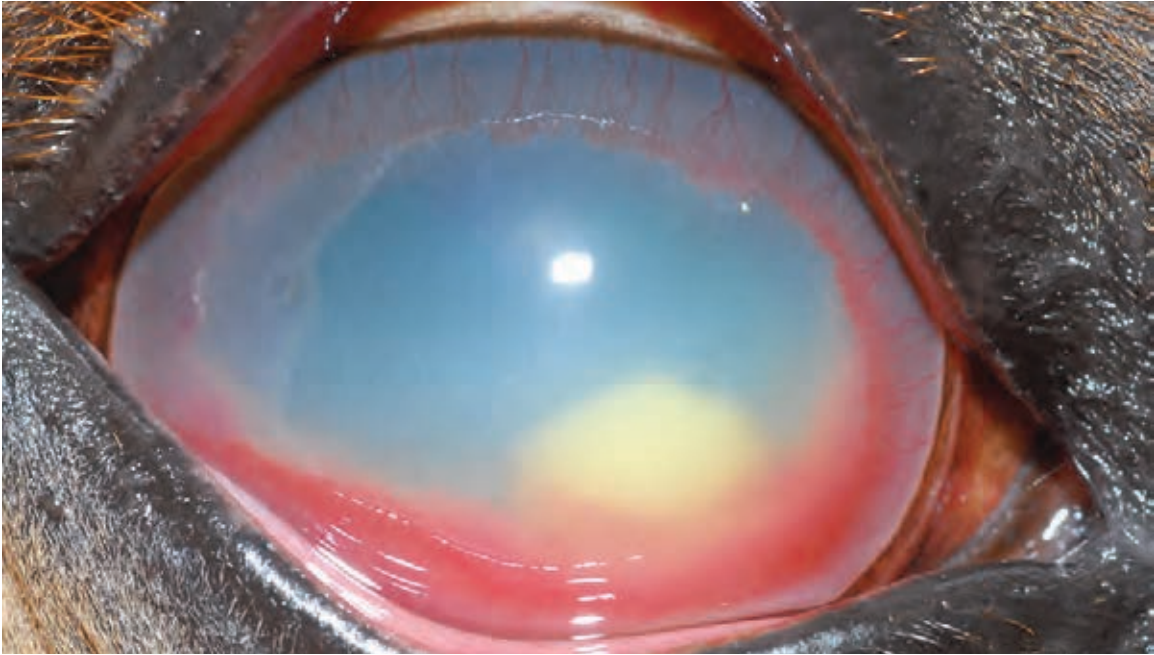


Figure 1: Typical appearance of a stromal abscess (Gilger, 2011).

A stromal abscess can be seen at any location in the cornea, and at various depths (superficial stromal, mid-stromal or endothelial). Abscesses located adjacent to the endothelium may rupture into the anterior chamber (Figure 2). This will cause severe inflammation within the eye, which can produce more consistent signs of pain. This can also be vision threatening.

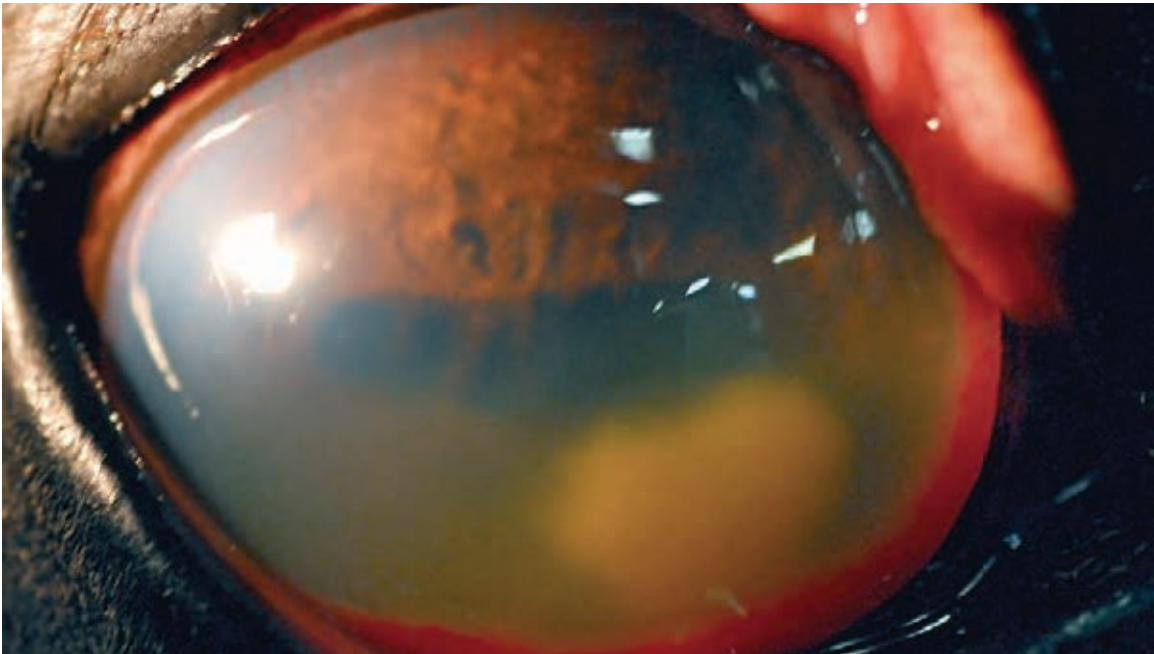


Figure 2: Stromal abscess that ruptured into the anterior chamber (Gilger, 2011).

The clinical signs can include sensitivity to light, squinting, tearing, and contracted pupils. Stromal abscesses often have a waxing and waning of clinical signs. There are periods of severe ocular pain, corneal opacity, and uveitis alternating with periods of mild clinical signs.

The diagnosis:

The key to diagnosing ocular disease is by looking! An ophthalmologist starts every ocular examination by describing what they see. A lot can be determined by the clinical appearance of the eye, and this holds true with stromal abscesses.

Aside from the appearance of the eye, and the clinical signs associated with it, there are other diagnostic measures. The ophthalmologist will perform a fluorescein stain, which is a dye that stains the eye if the epithelial layer of the cornea is not intact. It is often the case with stromal abscess that there is no stain uptake as re-epithelialization has occurred in the disease process, and thus, the cornea is intact. In addition, a cytology and culture are great diagnostic tools to determine if there are infectious components such as bacteria or fungus. Unfortunately, as the abscess is often sealed with in the stroma a good representative sample is difficult to obtain, as the epithelium is intact.

The mainstay of treatment:

Aggressive medical treatment is essential to manage stromal abscesses effectively. Often times a subpalpebral lavage catheter (catheter that sits beneath the eyelid) is placed to administer the medications (Figure 3). Medications include antimicrobials (antibiotics, and antifungals) to target bacteria and fungal organisms. These medications are given very frequently (every 2 to 4 hours) at first.

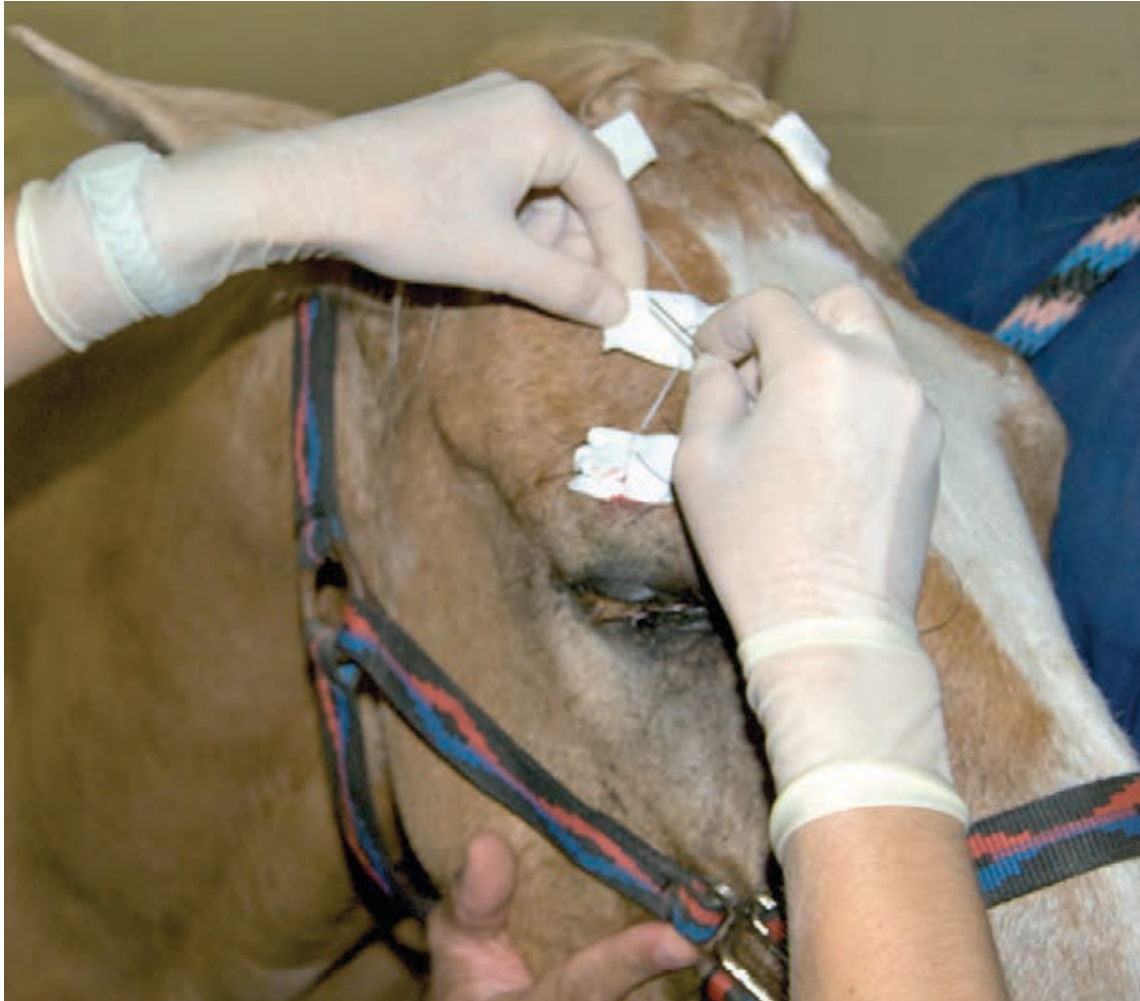

Figure 3: A subpalpebral lavage catheter placed in the upper eyelid for easier medication administration (Gilger, 2011).

Other medications are directed at making the eye more comfortable. Atropine is used topically to dilate the contracted pupil to help with ocular pain. Systemic anti-inflammatories (NSAIDs) are given to control inflammation and provide pain relief.

If the horse is not improving in the face of aggressive medical therapy then surgery may be warranted. Indications include if the horse remains painful or the abscess is progressing or getting larger. If the abscess does not resolve and severe inflammation persists this can lead to loss of vision or loss of the globe.

Prognosis depends upon aggressive, appropriate therapeutic intervention. With both surgical and medical intervention retention of the globe and vision is highly likely.

Take home message:

Don't let an eye problem wait! Have a veterinarian look at your horse if you have any concerns about the eye. Don't ignore the problem as more dire complications can arise.

Citations:

Gilger, Brian. Equine Ophthalmology. Maryland Heights, Saunders, 2011. PDF.

Hendrix D, Brooks D, Smith P, et al: Corneal stromal abscesses in the horse: a review of 24 cases, Equine Vet J 27: 440-447, 1995.

Rebhun W: Corneal stromal abscesses in the horse, J Am Vet Med Assoc 181: 677-679, 1982.